

Category:Cardiology

Pages in category "Cardiology"

The following 200 pages are in this category, out of 267 total.

(previous page) (next page)

-

- Arterial Catheter

3

- 3.2 ECG

A

- ABO system (English)
- Abdominal aorta
- Agents of cardiovascular infections
- Amplatzer's occluder
- Aneurysm
- Angina pectoris
- Angioinvasive Treatment Arterial Occlusion and Stenosis
- Angioinvasive treatment of arterial blockages and stenoses
- Angiotensin II receptor blockers
- Ankle pressure index
- Antiplatelet medications
- Aorta abdominalis
- Aorta thoracica
- Aortic regurgitation
- Aortic stenosis
- Aortic Valve Stenosis
- Arrhythmogenic cardiomyopathy
- Arterial hypertension
- Arterial reconstruction
- Arterial Reconstruction
- Arteriosclerosis
- Artery reconstruction
- Assessment of total cardiovascular risk
- Atrial Fibrillation
- Atrial fibrillation
- Atrial flutter
- Atrial septal defect

B

- Biochemical indicators of acute myocardial infarction
- Blood pressure measurment
- BMI
- Bradyarrhythmia
- Bradyarrhythmias and Bundle brand blockages
- Bradycardia
- Brugada syndrome
- Bypass

C

- Cardiac conduction system
- Cardiac inflammations (pediatrics)
- Cardiac markers
- Cardiac muscle contraction
- Cardiac Output
- Cardiac sarcoidosis
- Cardiac silhouette
- Cardiac Syndrome X
- Cardiac tamponade
- Cardiac tamponade (pediatrics)
- Cardiac tamponade (pediatry)

- Cardiogenic shock (CS)
- Cardiogenic shock (pediatrics)
- Portal:Cardiology
- CHA2DS2-VASc score
- Wells' score
- Cardiomegaly
- Cardiomyopathies
- Cardiomyopathy (CM)
- Cardioplegia
- Cardiotonics
- Cardiovascular disease in the elderly
- Central cyanosis
- CHA2DS2 - VASc score
- Chronic ischemic disease of the lower limbs
- Circulatory collapse
- Classification of shock (pediatrics)
- Clinical signs of shock (pediatrics)
- Clubbed fingers
- Coarctation of the aorta
- Congenital Heart Defects
- Congenital thrombophilia
- Constrictive pericarditis
- Contraction of the heart muscle
- Contrast echocardiography
- Cor pulmonale
- Coronary Blood Flow
- Coronary circulation
- Cystic medial necrosis
- Cystic medionecrosis

D

- Defibrillation
- Defibrillation and cardioversion 2
- Determination of cardiac output
- Diagnostic use of ultrasound
- Diastolic blood pressure
- Differential diagnosis of chest pain/PGS (VPL)
- Differential diagnosis of dyspnea/PGS (VPL)
- Dilated cardiomyopathy
- Dilated cardiomyopathy (pediatrics)
- Direct vasodilation
- Dissection of the thoracic aorta
- Distal diuretics
- Distributional shock (pediatrics)
- Diuretics
- Doppler echocardiography
- Dressler's syndrome
- Dromotropia
- Dyspnea

E

- Ebstein anomaly
- ECG examination
- ECG Leads
- Echocardiography
- Economy class syndrome
- Effect of drugs on heart rhythm
- Effects of poisons on heart rhythm
- Electrical cardioversion
- Electrocardiogram
- Electrocardiogram manifestations of disturbances of impulse generation and conduction
- Electrocardiography
- Electrocardiography (2. LF UK)/Evaluation
- Electrocardiography 2 (2. LF UK)
- Embolism
- End-diastolic volume
- Endocarditis
- Endocardium
- Endomyocardial biopsy
- Epicardium
- Examination of the arteries
- Examination of the child's cardiovascular system
- Examination of the child's cardiovascular system

- Examination of the child's Cardiovascular System
- Extrasystole

F

- Fats in diet
- Fibrinolytic system
- Foramen ovale patens

G

- Gestational cardiomyopathy

H

- Head-up tilt test
- Heart
- Heart Autorhythmicity
- Heart failure (internal)
- Heart failure/Repetitorium
- Heart inflammation
- Heart murmurs
- Heart rhythm disorders
- Heart rhythm disorders (neonatology)
- Heart Tumors
- Heart valves
- Heart whirl
- Heparin
- Home blood pressure monitoring
- Hypertension (paediatrics)
- Hypertrophic cardiomyopathy
- Hypertrophic cardiomyopathy/diagnosis
- Hypertrophic cardiomyopathy/treatment
- Hypolipidemic treatment
- Hypotension
- Hypovolemic shock (pediatrics)

I

- Infarct
- Infective endocarditis (pediatrics)
- Intraaortic balloon counterpulsation
- Invasive blood pressure monitoring (pediatrics)
- Ion exchangers
- Ischemic changes on the electrocardiogram
- Ischemic heart disease

K

- Kalium-sparing diuretics
- Kent's cluster
- Keshan disease

L

- Left bundle branch block

M

- Malignant arrhythmia
- Marfan syndrome
- Maze
- Mean arterial pressure
- Measurements of the Cardiac Output
- Metoprolol
- Migrating thrombophlebitis
- Migratory thrombophlebitis
- Myocardial Infarction
- Myocardial perfusion scintigraphy
- Myocarditis

N

- Natriuretic peptides

- Non-infectious endocarditis
- Non-invasive blood pressure monitoring (pediatrics)

O

- Obstructive shock
- Obstructive shock (pediatrics)
- One-dimensional echocardiography
- Osmotic diuretic

P

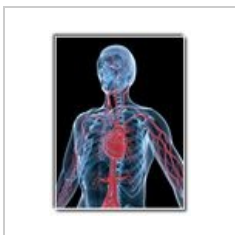- Pacemaker potencial
- Pacemaker potential
- PASP
- Patent ductus arteriosus
- Pericardectomy
- Pericardial friction murmur
- Pericardial window
- Pericardiocentesis
- Pericardiocentesis (pediatrics)
- Pericarditis (Pediatrics)
- Peripartum cardiomyopathy
- Peripheral cyanosis
- Peripheral vein cannulation
- Physiology and Pathophysiology of Shock (Paediatrics)
- Physiology and pathophysiology of shock (pediatrics)
- Postpericardiotomy Syndrome
- Pressure amplitude
- Primary Tumors of the Heart
- Principles of care for the patient in shock (pediatrics)
- Prinzmetal's angina
- Prinzmetal's angina pectoris
- Proximal tubule diuretic
- PTSMA
- Pulmonary ejection murmur
- Pulmonary embolism
- Pulmonary stenosis
- Pulmonary valve stenosis

Q

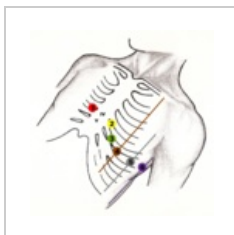
- Portal:Questions for final examination in Internal Medicine (1. LF UK, GM)
(previous page) (next page)

Media in category "Cardiology"

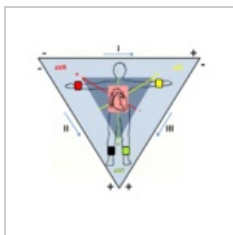
The following 7 files are in this category, out of 7 total.



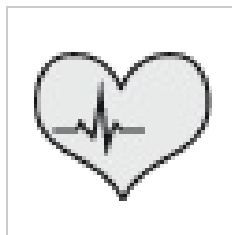Blood circulation...
333 × 433; 87 KB



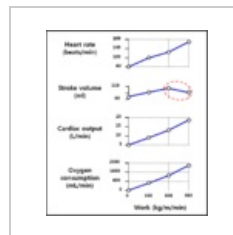
Chest leads.png
2,058 × 2,070;
4.55 MB



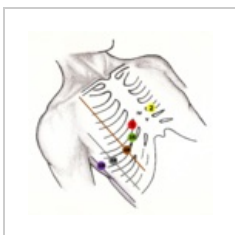
Einthoven.png
1,931 × 1,717;
1.26 MB



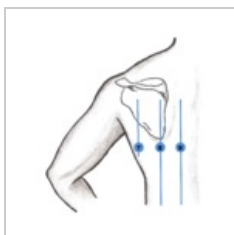
Kardiologie.png
50 × 50; 4 KB



Sportsphysiology...
750 × 857; 33 KB



V3R-V6R.png
2,081 × 2,069; 4.6
MB



V789.png
1,684 × 1,844; 1.5
MB

