

Canalis pudendalis

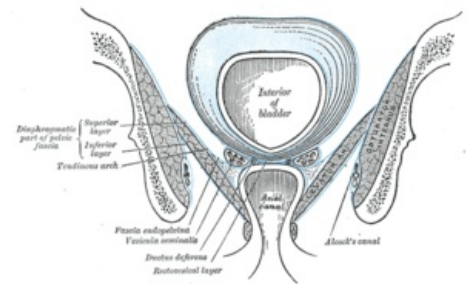
Canalis pudendalis (Alcocki - **Alcock's canal**) is a topographic space of the pelvis, which is taken in the lateral wall of the fossa ischioanalis in the fascia obturatoria. It takes place on the medial wall of the obturatorius internus muscle .

Content

- **vasa pudenda interna;**
- **n. pudendus.**

From this nerve-vascular bundle, the vasa rectalia inf., nn. rectales inf., n. and vasa perinealis, which reach up to the anus.

Numbness of the perineum and external genitalia can easily occur in *the canalis pudendalis* when suturing an episiotomy or perineal rupture.



Canalis pudendalis on the lateral wall of the fossa ischioanal

Links

related articles

- Ischioanal fossa

Source

- ČIHÁK, Radomír. *Anatomie 1*. 3. edition. Grada, 2011. 552 pp. ISBN 978-80-247-3817-8.
- GRIM, Miloš – DRUGA, Rastislav. *Základy anatomie : 5. Anatomie krajín těla*. 1. edition. Galén, 2008. 119 pp. ISBN 978-80-7262-179-8.