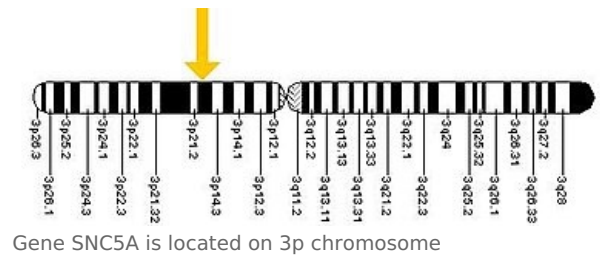


Brugada syndrome

The Brugada brothers managed to describe this syndrome in 1992. It is mostly an inherited disease with a typical ECG finding:

- 'incomplete blockade of Tawarov's right arm with concave elevation of ST' section in precordial leads (V1 – V3) [1].

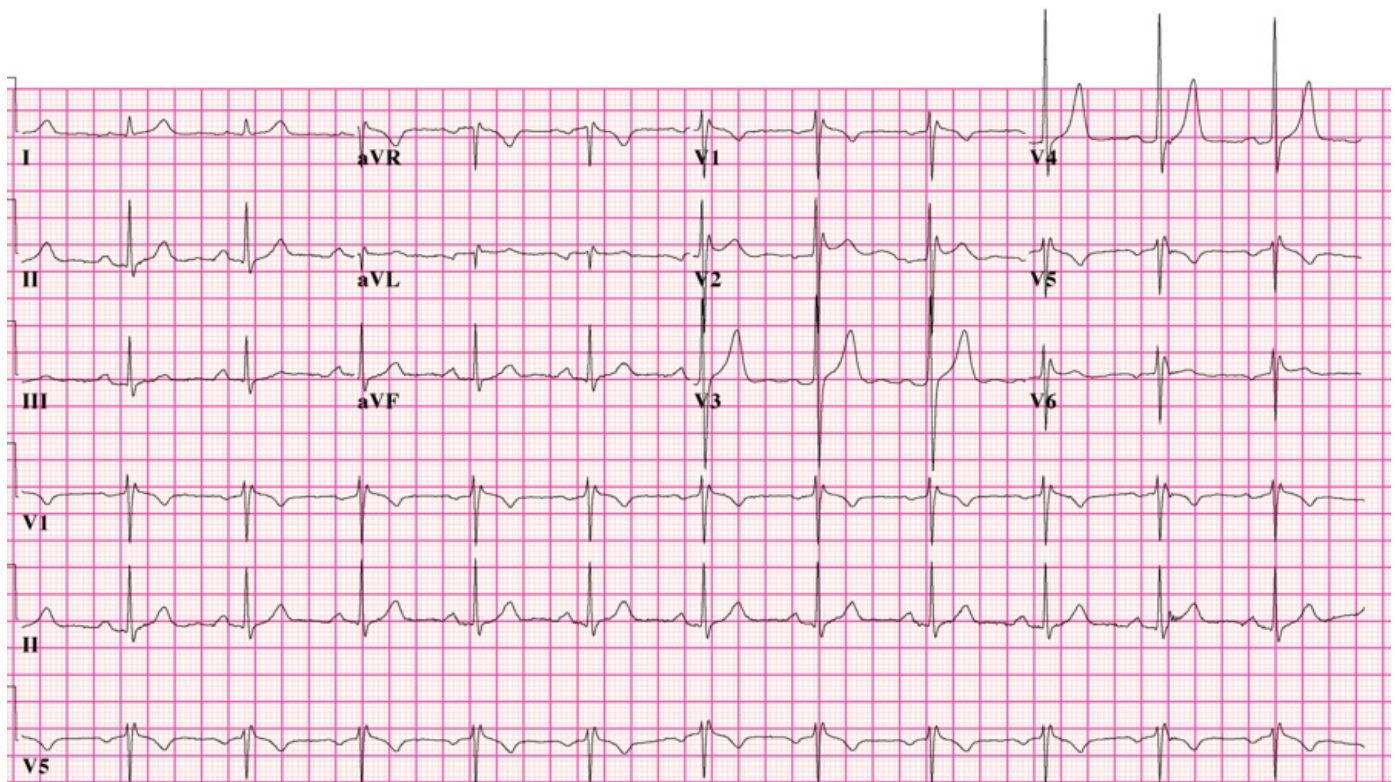
From an etiopathogenetic point of view, we speak of a 'genetic arrhythmogenic disease', which is characterized by AD inheritance with incomplete penetration. In some patients we find a mutation in the SNC5A gene for the α -subunit of the sodium channel (mutation of the same gene can also cause a specific type of long QT syndrome).



Gene SNC5A is located on 3p chromosome

An increased incidence of Brugada syndrome has been reported in men under the age of 50 in Southeast Asia and Japan.

Clinically manifested by syncope or sudden cardiac death due to ventricular tachycardia and ventricular fibrillation^{[2][3][4]}. [[



Brugada syndrome: picture of RSR in V1-V2, ST elevation best visible in V2.

Links

Related articles

- Long QT syndrome
- Ventricular fibrillation
- Sudden cardiac death
- Implantable cardioverter-defibrillator

External links

- Brugada syndróm (TECHmED) (<https://www.techmed.sk/brugada-syndrom/>)

References

1. BRUGADA, P – BRUGADA, J. Right bundle branch block, persistent ST segment elevation and sudden cardiac death: a distinct clinical and electrocardiographic syndrome. A multicenter report. *J Am Coll*

- Cardiol.* 1992, y. 20, vol. 6, p. 1391-6, ISSN 0735-1097. PMID: 1309182 (<http://www.ncbi.nlm.nih.gov/pubmed/1309182>).
2. KRIŠTOFOVÁ, Sabina – DVOŘÁK, Karel. Brugadaův syndrom jako příčina náhlého úmrtí. *Interv Akut Kardiol* [online]. 2004, y. 3, vol. -, p. 79-82, Available from <<http://www.solen.cz/pdfs/kar/2004/02/06.pdf>>. ISSN 1803-5302.
 3. NOVOTNÝ, Tomáš. Syndrom dlouhého intervalu QT. *Cor et Vasa*. 2007, y. 49, vol. 11, p. 416-425, ISSN 1803-7712.
 4. VOKURKA, Martin – HUGO, Jan. *Velký lékařský slovník*. 8. edition. 2009. ISBN 978-80-7345-166-0.

Source

- ws:Brugadaův syndrom