

Biceps femoris muscle

Origin:

1. caput longum – ischiatic tuber;
2. caput breve – labium laterale lineae asperae.

Attachment: capitulum fibulae.

Insertion: n. ischiadicus / with high cleavage: n. tibialis (caput longum), n. fibularis communis (caput breve).

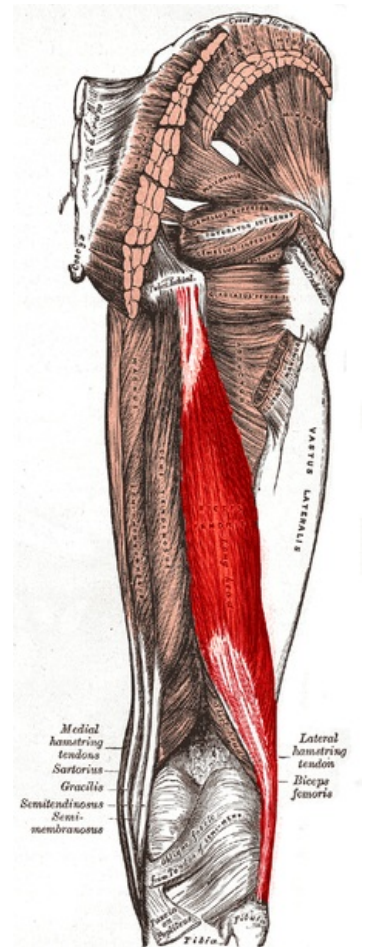
Function:

1. knee joint – flexion;
2. hip joint – extension, external rotation.

Links

References

- ŠIHÁK, Radomír – GRIM, Miloš. *Anatomy*. 2nd, edit. and add edition. Grada Publishing, 2002. 470 pp. vol. 1. ISBN 80-7169-970-5.
- VIGUÉ, Jordi. *Atlas of the Human Body*. 3. edition. Rebo, 2007. ISBN 978-80-7234-881-7.



Biceps femoris muscle
(long head highlighted)