

# Aspergillosis

The term **aspergillosis** includes a group of diseases that result from infection by one of the members of the genus *Aspergillus*.

There are four basic types of aspergillosis:

- **Invasive aspergillosis (IPA)** - occurs primarily in patients with severe immunodeficiency.
- **Allergic bronchopulmonary aspergillosis (ABPA)** - common in patients with atopy, asthma or cystic fibrosis
- **Chronic necrotizing pulmonary aspergillosis** - described in patients with chronic lung disease and mild immunodeficiency.
- **Aspergilloma** - can be found to a greater extent in patients with pre-existing cavities in the lungs.

## Invasive aspergillosis

It is an infectious disease with high morbidity and mortality in immunocompromised patients caused by fungi of the genus *Aspergillus*, most often *A. fumigatus*.

## Epidemiology

Aspergils are **ubiquitous**, occurring in the air, soil, dust, building materials, some foods, and water. The main route of entry for aspergillus is **the respiratory tract**. After inhalation, **conidiospores** mature in the lungs and can also penetrate other tissues through blood vessels if they are not controlled by the body's defense mechanisms.

However, most people are naturally immune to the development of the disease because alveolar macrophages have the ability to absorb and destroy conidia. However, in patients treated with corticosteroids and in immunodeficient patients (patients with leukemia, AIDS, COPD, patients after chemotherapy or transplantation, etc.), this ability is reduced.

## Risk factors

The main risk factors for the development of IPA are **neutropenia**, **solid organ transplantation** (especially lung), **stem cell haematopoietic stem cell transplantation (HSCT)**, **chronic obstructive pulmonary disease (COPD)**, **systemic corticosteroid therapy** and **haematological malignancies**.

Other risk factors such as liver and renal failure, HIV, diabetes mellitus, malnutrition, autoimmune diseases and extensive burns have also been described.

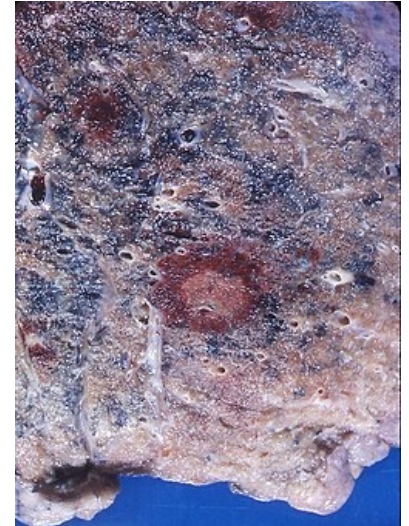
In most cases, aspergils are taken in the lower respiratory tract by inhalation of infectious spores. Less often, IPA can start from other sites, namely the paranasal sinuses, gastrointestinal tract and skin. The infection can spread through the bloodstream to other organs such as the brain, kidneys, liver, heart, pleura, etc.

## Symptoms

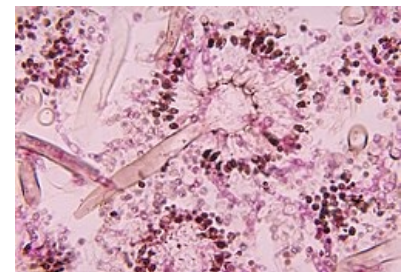
The symptoms are non-specific and resemble bronchopneumonia: fever, cough, sputum formation, dyspnoea, chest pain of pleural origin due to vascular invasion leading to thrombosis and small pulmonary infarction, hemoptysis.

## Diagnostics

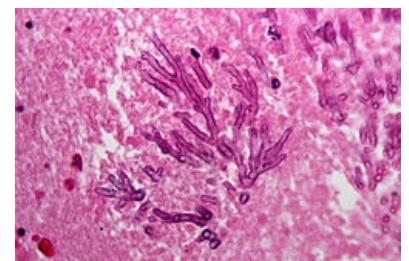
The golden standard in the diagnosis of IPA is **histopathological examination** - samples of lung tissue obtained by thoracoscopy or open lung biopsy for the presence of septated, branched hyphae and **positive cultures**. Other options are sputum examination, BAL fluid, chest CT examination (presence of nodules and **halo sign** - weakening zone around the lung nodules caused by hemorrhage and typical for neutropenic patients), ELISA test for detection of aspergillus antigens in body fluids (*galactomannan* - polysaccharide released from aspergillus after growth time) and PCR.



Aspergillosis



Histopathological picture of aspergillosis.



Fatal cerebral aspergillosis in an immunocompromised child. HE stain.

## Therapy

Due to the possible progression of the disease, it is recommended to start treatment when IPA is suspected, before the diagnosis is confirmed by laboratory tests. Commonly used drugs are **liposomal amphotericin B**, **voriconazole** and echinocandin derivatives such as **caspofungin** or **miconazole**.

## Allergic bronchopulmonary aspergillosis

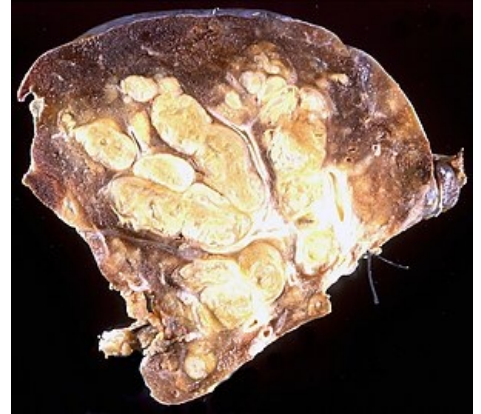It is a disease that develops in **hypersensitivity** to aspergillus antigens, mainly *A. fumigatus*. Most cases occur in people with asthma and cystic fibrosis. The incidence is also higher in people with atopy.

### Clinical picture

In ABPA, the lungs show reversible **obstructive changes**, which, however, may progress to irreversible changes at more advanced stages. **Restrictive lung disease** with reduced diffusion capacity due to mucus and hyphae compression and **central bronchiectasis** (CB) develops.

ABPA is divided into five stages:

- **acute** - initial phase characterized by asthma, elevated IgE levels, **eosinophilia**, pulmonary **infiltrates** and **IgG** and **IgE** antibodies against *A. fumigatus*,
- **remission phase** - symptoms weakened (reduced),
- **exacerbation** - recurrence of initial symptoms, IgE levels **double**
- phase occurring in patients with asthma dependent on regular use of corticosteroids - asthma worsens, bronchiectasis develops
- **fibrotic phase** - development of fibrosis in the upper lobes of the lungs.



manifestation of allergic bronchopulmonary aspergillosis.

### Symptoms

Patients experience **episodic wheezing**, **sputum coughing** with brown coatings, **chest pain of pleural origin**, and **fever**.

### Diagnostics

Diagnostic criteria for ABPA are **asthma**, immediate **skin reaction** to Aspergillus, presence of **IgG** and **IgE** against *A. fumigatus* in the blood, IgE level higher than **1000 IU / ml**, incidence of pulmonary **infiltrates** on the CT of the chest, **eosinophilia** (1000 cells /  $\mu$ l).

## Therapy

Most cases require treatment with systemic corticosteroids. **Corticosteroids** (suppression of hypersensitivity and inflammatory response). The drug of choice is mainly **prednisone**. In some cases, **itraconazole** is also used.

## Chronic necrotizing pulmonary aspergillosis

Chronic necrotizing aspergillosis (CNPA, semi-invasive or subacute invasive aspergillosis) is an **infectious process of the lung parenchyma** that develops in response to local invasion commonly *A. fumigatus*.

### Clinical picture

This is a **rare syndrome** and, unlike IPA, CNPA develops slowly, over several weeks to months, and vascular invasion or dissemination to other organs usually does not occur. It can be difficult to distinguish from aspergillosis. However, in the case of CNPA, this is a **local invasion of the lung parenchyma**, and a cavity filled with Aspergillus may form secondarily as a result of fungal tissue damage. CNPA is characterized by **necrosis of lung tissue**, acute or chronic inflammation of the cavity wall, and the presence of **hyphae**.

### Risk factors

It mainly affects the older part of the population with chronic lung diseases such as **COPD**, pulmonary tuberculosis, pneumoconiosis, cystic fibrosis, sarcoidosis, pulmonary infarction.

### Symptoms

Patients often complain of **fever**, **malaise**, **fatigue**, **weight loss**, **chronic productive cough** and **hemoptysis**. However, the course of CNPA can also be asymptomatic.

## Diagnostics

Chest CT is used in the diagnosis of CNPA, on which pleural thickening is visible, which can lead to the formation of broncho-pleural fistula and cavity lesions in the upper lung lobes. In most patients we also find serum IgG antibodies against *A. fumigatus*. Histopathological examination and cultivation are essential to confirm the diagnosis.

## Therapy

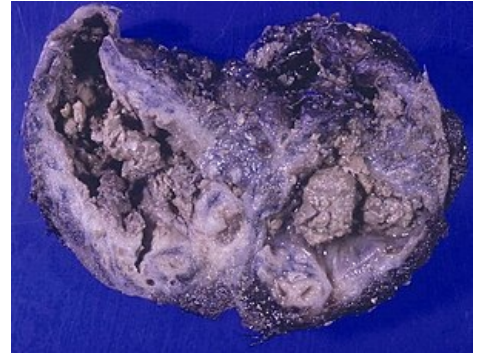**Voriconazole** or **itraconazole** are most commonly used to treat mild to moderate forms of CNPA , with severe forms being treated with **amphotericin B** and intravenous **voriconazole**.

# Aspergilloma

It is the most common form of **aspergillosis**. It consists of a **conglomerate of hyphae, mucus, fibrin** and **inflammatory cells** in a pre-existing **cavity** in the lungs.

## Clinical picture

The conglomerate can move within the cavity, but usually does not penetrate the surrounding parenchyma or blood vessels. The lesions usually remain permanent, sometimes they may shrink or disappear spontaneously, rarely they may enlarge. In some cases, they can cause **heavy bleeding** by damaging the bronchial vessels or the vessels surrounding the cavities. Predisposing factors for the development of aspergillosis may be previously established pathological cavities, such as conditions after **tuberculosis, sarcoidosis, bronchiectasis, bronchial cysts, ankylosing spondylitis** or **lung infections**. <sup>[1]</sup>



Multiple aspergillomas within large cavitory lesions of tuberculous origin.

## Symptoms

Most patients develop **hemoptysis**, which can be mild but also life-threatening. Other symptoms include **cough, dyspnoea** and **fever**.

## Diagnostics

The diagnosis is based on an **X-ray** or **CT of the chest**, which shows the site of the lesion on the lungs. Sputum culture is positive in only **50% of cases**, whereas IgG antibodies against *A. fumigatus* are present in most cases.

## Therapy

Treatment is started when the patient is symptomatic, especially after the development of haemoptysis . The drug of choice is **itraconazole**. **Surgical resection** of aspergilloma is commonly indicated for recurrent hemoptysis. **Bronchial artery embolization** is recommended in patients with life-threatening hemoptysis. <sup>[2]</sup>

## Links

### Related articles

- Allergic bronchopulmonary aspergillosis
- Invasive aspergillosis
- CNPA
- Aspergillus
- Aspergillus infections
- Invasive fungal infections

### External links

- Aspergillosis, The Aspergillus Website (<https://www.aspergillus.org.uk/aspergillosisframeset.html>)
- Aspergillosis, MedlinePlus (<https://medlineplus.gov/ency/article/001326.htm>)
- Aspergillosis, Medscape (<https://emedicine.medscape.com/article/296052-overview>)
- Aspergillosis, NHS Choices (<https://www.nhs.uk/conditions/aspergillosis/>)
- What is aspergillosis, National Aspergillosis Centre (<http://www.nationalaspergillosiscentre.org.uk/>)

## Reference

1. SOUBANI, Ayman O – PRANATHARTHI, H CHANDRASEKAR. The clinical spectrum of pulmonary aspergillosis. *Chest [online]* [online]. 2002, vol. 121, p. 1988-99, Available from <<https://www.ncbi.nlm.nih.gov/pubmed/12065367>>. ISSN 978-80-7387-423-0.
2. JUDSON, M A – D A, STEVENS. The treatment of pulmonary aspergilloma. *Curr Opin Investig Drugs [online]* [online]. 2001, vol. 2, p. 1375-7, Available from <<https://www.ncbi.nlm.nih.gov/pubmed/11890350>>. ISSN 1472-4472.

## References

- KOUSHA, M – TADI, R – SOUBANI, A.O. Pulmonary aspergillosis: a clinical review. *European Respiratory review* [online]. 2011, y. 2011, no. 121, p. 156-162, Available from <[www.ersjournals.com](http://www.ersjournals.com)>. ISSN 1600-0617. DOI: 10.1183/09059180.00001011 (<http://dx.doi.org/10.1183/09059180.00001011>).
- WILLEY, Joanne M – SHERWOOD, Linda M – WOOLVERTON, Christopher J. *Prescott, Harley, and Klein's Microbiology*. 7. edition. New York : McGraw-Hill Hogher Education, 2008. 1088 pp. ISBN 978-0-07-299291-5.
- SCHAECHTER, Moselio – LEDERBERG, Joshua. *The desk encyclopedia of microbiology*. 1. edition. Amsterdam : Elsevier, 2004. ISBN 0-12-621361-5.