

Arteria ulnaris

Arteria ulnaris descends from the division of *a. brachialis* under caput commune ulnare between *m. flexor carpi ulnaris* a *m. flexor digitorum superficialis*.

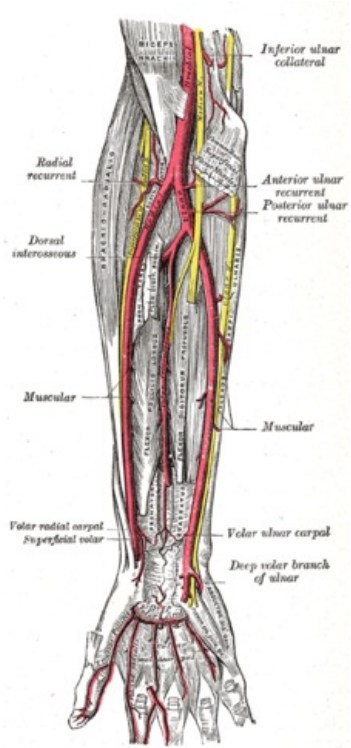
It branches out a. interossea communis, which divides into a. interossea anterior, posterior and a. commitans nervi mediani (during development is the main artery of the limb).^[1] Further branches out *rete carpi palmare* and *dorsale*, goes through *canalis ulnaris* (Guyon canal)^[2], then branches out ***r. palmaris profundus*** to **arcus palmaris profundus** and makes **arcus palmaris superficialis**.

It supplies muscles of the front and dorsal gruop , *m. supinator*, palm , back of a hand and fingers, the skin in the medial position of the forearm.^[1]

Reference

Reference

1. ČIHÁK, Radomír. *Anatomie 3*. 2. edition. Praha : Grada Publishing, 2004. 692 pp. ISBN 978-80-247-1132-4.
2. HOLEK, Martin. *Anatomie končetin pro zimní pítěvnu [elektronický zdroj] : (neprodejná skripta pro studenty prvního ročníku 3. LF UK)*. 1. edition. Univerzita Karlova, 3. Lékařská fakulta, 2009. ISBN 978-80-254-3223-5.



Arteria ulnaris

TA	A12.2.09.041
Descends from	a. brachialis
Branches	a. recurrens ulnaris, rete articulare cubiti, a. nutricia ulnae, a. interossea com., r. carpalis dors., r. carpalis palmaris, r. palmaris prof., arcus palmaris spf., aa. digitales palmares com.