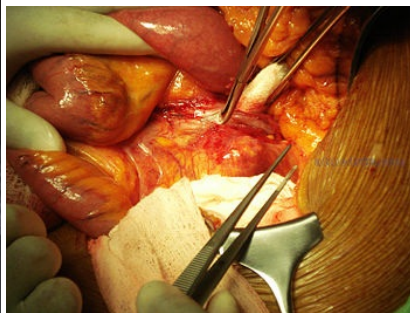
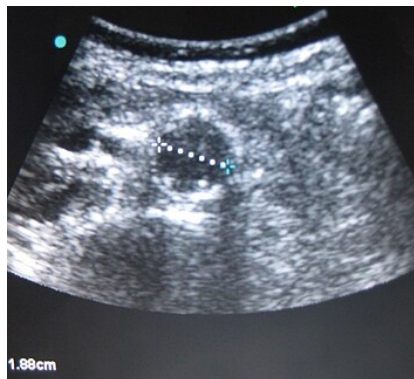

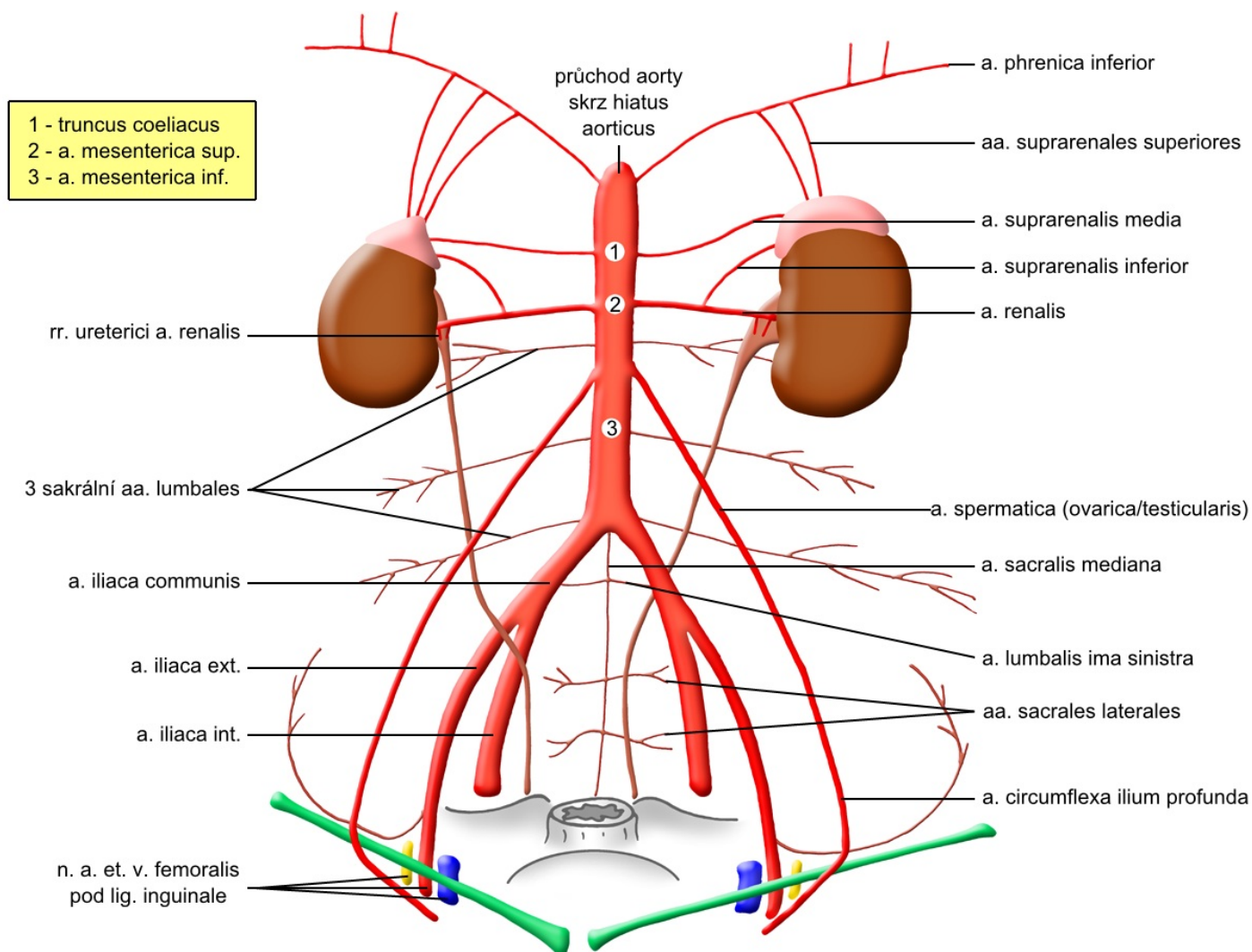
# Aorta abdominalis

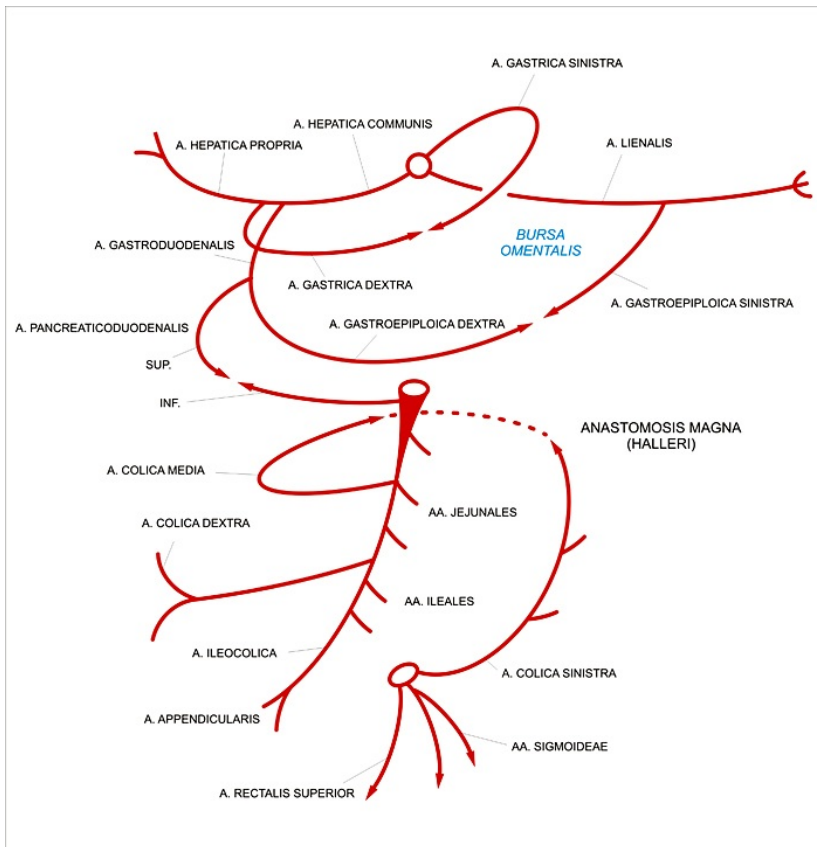
This article has been translated from WikiSkripta; the **translation** needs to be checked.  
 This article has been translated from WikiSkripta; the **formatting** needs to be checked.  
 This article has been translated from WikiSkripta; ready for the **editor's review**.



A12.2.02.001 (<http://www.unifr.ch/ifaa/Public/EntryPage/TA98%20Tree/Entity%20TA98%20EN/12.2.02.001%20Entity%20TA98%20EN.htm>)

**visceral** : pair (aa. suprarenales mediae, aa. renales, aa. testiculares / ovaricae), unpaired ( truncus coeliacus , a. mesenterica superior, a. mesenterica inferior); **parietal**: aa. phrenicae inf., aa. lumbales, aa. common iliacae





The **abdominal aorta** forms an unpaired continuation of the thoracic aorta and transports oxygenated blood to all abdominal and pelvic organs, supplying the muscles of the back, abdominal walls and diaphragm, external genitalia and lower limbs. The abdominal aorta runs close to the spine along the left flank of the inferior vena cava from the diaphragm *aorticus* (Th12 level) to its *bifurcation* (L4), where it divides into the **iliacae communes (a. Iliaca communis dextra et sinistra)**, which then continue to pelvic area, where it further branches. The abdominal aorta has several groups of branches. The basic aspect of the division is the fact that some branches supply the organs, while others participate in the supply of the surrounding walls. Accordingly, we recognize:

- parietal (wall) branches;
- visceral (organ) branches.

The **parietal** branches of the abdominal aorta include **aa. phrenicae inferiores extending** just below the aortic hiatus and extending along the lower surface of the diaphragm, 4 pairs of **aa. lumbales, a. sacralis mediana** forming an unpaired continuation of the abdominal aorta and **aa. common iliacae**. **Aa. Phrenicae inferiores** are involved in the supply of the diaphragm and also contribute to the nutrition of the adrenal glands (aa. suprarenales superiores). **The lumbar arteries** are a continuation of the thoracic intercostal arteries (branches of the thoracic aorta) and supply the corresponding sections of the lumbar region and abdominal wall. **Aa. iliacae** completely supply the lower half of the body.

**Visceral** branches of the abdominal aorta can be further divided into:

- paired
- unpaired

Typical **unpaired branches** include craniocaudally:

- **Truncus coeliacus**

Truncus coeliacus is a very short branch, which is only a few centimeters from its distance in the Th12 / L1 area divided into 3 main branches - **a. splenica** supplying the large gastric curvature, body and tail of the pancreas and spleen, **a. gastrica sinistra** running along the small gastric curvature and supplying the pars abdominalis of the esophagus and **a. hepatica communis** nourishing the area of the large curvature, **duodenum, pancreatic head and liver** with **gallbladder**.

- **A. mesenterica superior**

A. mesenterica superior (spaced about 2 cm caudally from the truncus coeliacus behind the head of the pancreas, level L1) is the main branch for the duodenum (aa. Pancreaticoduodenales inferiores), jejunum (aa. Jejunales), ileum (aa. Ileales), caecum (a. ileocolica), colon ascendens and colon transversum (a. colica dextra) up to the *Cannon-Böhm* point (about 2/3 colon transversum). Outside the [small|small intestine], appendix and large intestine, the mesenteric artery it is also involved in the supply of the head of the pancreas, it can send branches also for the stomach and in up to 30% of cases even an additional *hepatic artery*.

- **A. mesenterica inferior**

A. mesenterica inferior (distance at the level of the upper part of the L3 vertebra) is followed by a supply to the. (anastomosis with a. colica media - *anastomosis magna Haleri*) and supplies blood for the rest of the colon transversum, for the colon descendens (a. colica sinistra), sigmoid (aa. sigmoideae) and rectum (a. rectalis superior), where it anastomoses with paired **aa. rectales mediae** (from the internal iliac artery), which allows partial (but not entirely sufficient) compensation in the event of obstruction of one of these arteries.

**The paired branches of the** abdominal aorta are:

- **aa. suprarenales mediae** supplying the right and left adrenal glands;
- **aa. renales** (a. renalis dx. et sin.) for both kidneys and as a lower branch for the adrenal glands (aa. suprarenales inferiores);
- **aa. testiculares/ovaricae** (a. testicularis / ovarica dx. et sin.) nourishing the gonads (testicles / ovaries).

## References

### Related Articles

- Abdominal aortic aneurysm
- Elastic artery (histological specimen)
- Thoracic aorta

- Aortic regurgitation
- Aortic stenosis

## References

- ČIHÁK, Radomír. *Anatomie III*. 2., upr. a dopl edition. Praha : Grada Publishing, spol. s. r. o., 2004. 673 pp. ISBN 80-247-1132-X.