

Anton-Babinski syndrome

A rare syndrome characterized by **anosognosis of blindness**. Symptoms of this syndrome are **cortical blindness, confabulation, confusion states, and cognitive deficit**.

Etiology

- Stroke,
- Brain trauma,
- adrenoleukodystrophy,
- MELAS syndrome.

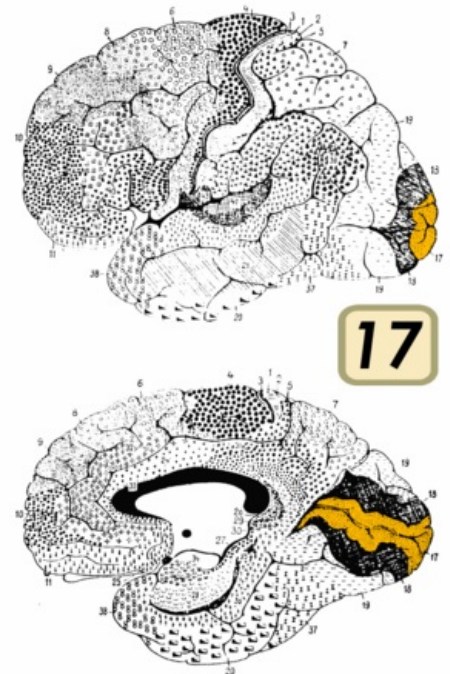
Pathogenesis

Cortical blindness is caused by a **bilateral lesion of the primary visual centers** in area 17 around the *fissura calcarina*. By simultaneously affecting the secondary visual centers in areas 18 and 19 and the parietal lobe, in which the secondary visual centers partially interfere, they cause anosognosia of blindness. Damage to the frontal lobe efferent also plays a role. Lesions of the parietal lobe and joints of the frontal lobe cause subsequent confabulations.

Confusion states and cognitive disorders are probably caused by lesions of the joints leading from the secondary visual centers to some parts of the limbic system. The syndrome is manifested by a complex involvement of the cortex and subcortical joints, in which the above-mentioned partial lesions must be properly treated.

Clinical picture

The patient **denies that he is blind**, even though he is actually blind. He compensates for the zero visual input with confabulations - when he asks what he sees, he describes people or things that are not present, and he trusts them himself. Sometimes he can admit only a slight deterioration in his eyesight, but he does not admit that he cannot see. Cognitive disorders and states of confusion or concentration disorders are also part of the syndrome.



Brodman area 17,18,19

Links

Related articles

- Prefrontal syndrome
- Frontal lobe syndrome
- Roland syndrome
- Parietal lobe syndrome
- Temporal lobe syndrome
- Functional cortical areas

References

- MILER, Michal. Antonův-Babinskiho syndrom. *Neurologie pro praxi* [online]. 2010, y. 11, no. 2, p. 126-128, Available from <<http://www.neurologiepropraxi.cz/pdfs/neu/2010/02/13.pdf>>. ISSN 1803-5280.
- NEVŠÍMALOVÁ, Soňa – RŮŽIČKA, Evžen – TICHÝ, Jiří, et al. *Neurologie*. 1. edition. Praha : Galén, 2002. 368 pp. pp. 15. ISBN 80-7262-160-2.
- HUDÁK, Radovan – KACHLÍK, David, et al. *Memorix anatomie*. 3. edition. 2016. pp. 437. ISBN 978-80-7387-959-4.