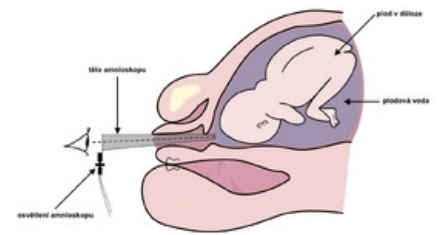


# Amnioscopy

**Amnioscopy** is an endoscopic examination method used in obstetrics, where **the quality and color of the amniotic fluid is visually examined** using an amnioscope. The amnioscope is a conically tapering tube with a light source, which is introduced through the vagina and the canal of the cervix to the lower pole of the sac of membranes. Physiologically, **the amniotic fluid is clear**, it may contain amniotic fluid flakes. A different color of the amniotic fluid points to the possibility of an intrauterine threat to the fetus. As a standard, amnioscopy is performed when the mother is admitted to the delivery room (so-called **entrance amnioscopy**).



Amnioscopy

- *The green color* of the amniotic fluid can signal hypoxia of the fetus (the green color is conditioned by the leakage of meconium from the intestine; cardiotocography and ultrasound flowmetry are much more perfect methods of detecting hypoxia of the fetus).
- *Yellow coloration* of the amniotic fluid can signal a hemolytic disease of the fetus in Rh-isoinmunization.
- *Brown coloration* of the amniotic fluid may signal intrauterine death of the fetus.

**⚠ Only the anterior amniotic fluid can be examined with an amnioscope.**

## Links

### Related articles

- Fetoscopy
- Prenatal diagnosis

### Literature

- ČECH, Evžen – MARŠÁL, Zdeněk, et al. *Porodnictví*. 1. edition. Praha : Grada, 1999. ISBN 80-7169-355-3.