

Acute abdomen in gynecology

Sudden Abdominal Events are characterized by a sudden *emergence from full health*. They have a rapid course, are life-threatening and usually require immediate surgery. They usually lead to impending or developing shock, sometimes with serious complications (DIC, MODS).

Diagnostics

Abdominal emergencies are usually diagnosed by a field doctor. Based on the anamnesis and the physical findings, it is necessary to decide whether it is a sudden event. Then, if necessary, it ensures vital functions and accelerated transport to the inpatient facility. The institutional physician then performs a differential diagnosis and determines the type of sudden event. We distinguish whether NPB is **inflammatory, ileotic or hemorrhagic**. It is necessary to find out the cause and distinguish the affected organ, we will decide whether to treat conservatively or surgically.

Examination

- Vital signs – state of consciousness, blood pressure, heart rate, pulse wave quality, rate and type of breathing, skin color;
- we monitor the activity of the uropoietic system - diuresis, dysuria, stranguria, hematuria, anuria, nephrolgia;
- we monitor the activity of the GIT - vomiting, passing stool and gases, the nature of peristalsis;
- maternal bleeding, temperature, nature of pain;
- until the cause of NPB is clarified, we do not administer drugs that would suppress the clinical picture (ATB, corticoids, opioids, spasmodalgesics, antipyretics and laxatives).

Objective finding

- **muscular defense** (in case of irritation of the peritoneum): may not be significant in the elderly, pregnant and six-month-old women, in the malnourished; paradoxically, it can occur when abdominal or thoracic organs are injured, with pneumonia, with AIM;
- **Blumberg, Rovsing and Lanz**: they can be negative in pelvic and retrocecal appendicitis;
- **Lennander's sign**: difference in temperature in the axilla and in the rectum by more than 1 °C.

From a differential diagnostic point of view, we divide events into NPB of gynecological origin, gynecological external bleeding and states of unconsciousness.

Sudden abdominal events in gynecology

Sudden abdominal events in gynecology are often associated with bleeding and require surgery. If they are inflammatory, they are usually well defined in the pelvis, and conservative treatment can also be chosen in the elderly. Pain dominates in sudden abdominal events - it can be diffuse, localized, colicky, visceral and somatic.

One of the most common sudden abdominal events during pregnancy are

- Ectopic pregnancy;
- rupture of hemorrhagic cyst (ovarian apoplexy);
- PID with abscess rupture;
- torsion of adnexa;
- torsion of a pedunculating myoma.

According to the localization of the pain, we distinguish between right and left lower abdominal pain syndrome

1. **Algic syndrome of the right lower abdomen:**
 - surgical causes: appendicitis, gastroenteritis, inflammation or lithiasis of a low-lying gallbladder, perforation of a duodenal ulcer, lymphadenitis mesenterialis, Crohn's disease, inflammation of Meckel's diverticulum, carcinoid appendix, torsion of the omentum;
 - gynecological causes: extrauterine gravidity, adnexal torsion, adnexitis, acute pelveoperitonitis, tuboovarian abscess, rupture of follicular or corpusluteal cysts, ovulation crisis;
 - urological causes: renal colic, ren migrans, hydronephrosis;
 - internal causes: pneumonia, pleurisy.
2. **Algic syndrome of left lower abdomen:**
 - less frequent, usually of gynecological or urological origin.

Extrauterine pregnancy

The most common sudden event in gynecology, a more accurate term is ectopic pregnancy (because cervical and isthmic pregnancies are also counted here and they are intrauterine). The blastocyst attaches ectopically in 0.5% of pregnancies, the incidence has been increasing recently.

Localization - it is most often in the fallopian tube (95-97 %):

The grooved egg has the ability to nidate (from day 6), the most suitable place is the endometrium, but it can attach anywhere in the internal genitalia or on the serous membranes. Exceptionally, it happens that it begins to develop in the cervix uteri, this pregnancy tends to have the most serious course (repeated, difficult-to-treat bleeding occurs there, often a life-saving hysterectomy must be performed).

Causes

Inflammations – cause semi-obstruction of the tube (these semi-occlusions are more likely due to ATB therapy). Intrauterine contraceptives increase the probability, but probably also hormonal and fallopian tube endometriosis.

Development of a nested egg

The trophoblast invades the surrounding tissues, it can take place in different ways. The embryo may die shortly after nidation - this is then considered delayed menstruation.

If the egg is larger and the villi of the chorion break the vessels of the fallopian tube, bleeding occurs in the egg shell, it separates, and **tubal moles** are formed. It often happens that the contraction of the fallopian tube expels the egg into the abdominal cavity - **abortus tubarius**. If the trophoblast erodes the entire wall, a **rupture of the fallopian tube** can occur, which has a turbulent course, there is a risk of bleeding, because the blood practically does not clot (fibrinogen precipitates when it comes into contact with the peritoneum).

Rarely, the egg is expelled into the abdominal cavity and an **abdominal pregnancy** occurs, when the fetus is stored in the Douglas's space, rarely it can be carried to term (but this does not entitle us to proceed conservatively - detected abdominal pregnancy is always indication for laparotomy).

A woman's organism goes through similar changes as during a normal pregnancy - the uterus is enlarged, the endometrium is decidually changed, the mammary gland reacts by swelling.

Diagnosis of ectopic pregnancy

Diagnosis is difficult, especially in intact pregnancy without hemoperitoneum.

Anamnesis

We are looking for gynecological infections, intrauterine contraception, previous ectopic pregnancy.

Clinical picture

Cycle disorder, pain, irregular bleeding, finding of an adnexal tumor, indirect signs of pregnancy - morning vomiting dominate. Also present are lividity of the parents, slight enlargement of the uterus, persistent rise in basal temperature. In hemoperitoneum, the space of Douglas is reduced and painful.

Tubal abortion is manifested by colic pains (as the tube tries to expel the egg). Tubal rupture - sudden pain in the lower abdomen, peritoneal irritation, collapsed state, hemoperitoneum, cardiopulmonary decompensation, shock state.

Oehlecker's sign - pain shooting under the shoulder blade (phrenic irritation when lying down). Herzfeld's and Myelan's sign - urge to urinate and defecate. Soloviev's sign - with retrouterine mole. due to the pressure and friction of blood clots, a sound similar to the crunch of melting snow is produced in the posterior vault of the vagina.

Punction of Douglas space

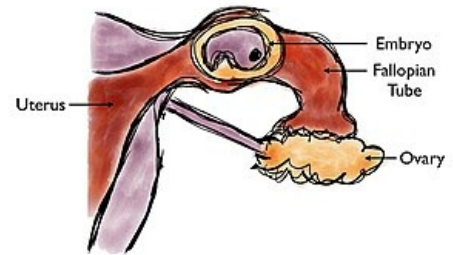
We find hemoperitoneum - dark, non-coagulating blood. Today it is not performed so much, it is replaced by USG.

USG High mucosa in the uterus, we can see an adnexal tumor, extrauterine heartbeat of the embryo, fluid in the space of Douglas; arterial doppler – increased flow is suspicious.

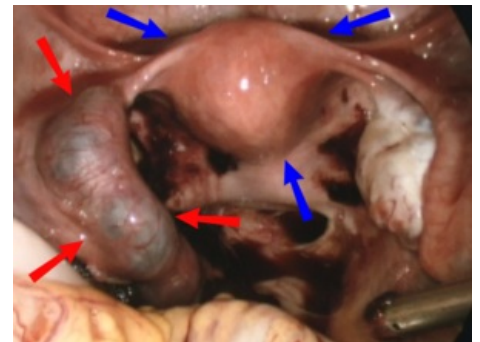
Determination of hCG

Especially in an intact pregnancy, the egg develops poorly ectopically, so the levels are lower than would correspond to the length of amenorrhea.

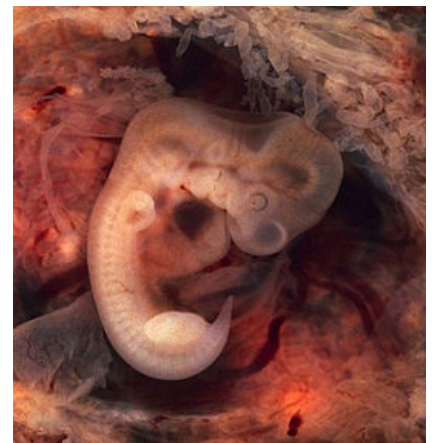Doubling time extended. Hysterosalpingography - has lost its importance today.



Ectopic pregnancy in fallopian tube



Ectopic pregnancy and hematosalpinx - red arrows, uterus - blue arrows



Differential diagnosis

Other conditions associated with bleeding – rupture of follicular or corpus luteal ovarian cyst. Appendicitis, adnexitis, residues after spontaneous abortion, duplicate pregnancy (it is both extrauterine and intrauterine).

Therapy

In the therapeutic balance, we are guided by age, parity, local and general findings and the woman's requirement to preserve reproductive function.

Conservative methods

Fetal expression. egg/dissection of the fallopian tube (partial resection of the tube is not performed, as it increases the risk of additional GEU, in addition, there is a high probability of post-operative obstruction of the fallopian tube).

Radical therapy (salpingectomy)

We mostly operate laparoscopically (we usually perform a diagnostic laparoscopy and immediately follow up with therapy). In severe conditions with a lot of blood loss.

Medical therapy

It is possible both overall and locally, when under USG control we introduce substances causing its death (prostaglandins, cytostatics) into the fetal egg. This procedure is only suitable for very early pregnancies.

Torsion of adnexa

Adnexal torsion is the second most common **NPB** in gynecology after ectopic pregnancy. Torsion of a movable ovarian tumor or pedunculated myoma occurs (but torsion of a healthy fallopian tube can also occur).

Clinical picture

It takes place suddenly or gradually (it depends on how big the strangulation is). If there is a partial rotation, the veins are compressed, the arterial inflow remains preserved - there is congestion in the cyst, swelling or bleeding . If there is also strangulation of the arteries, necrosis and an inflammatory reaction of the peritoneum develops . With multiple torsion - severe pain, often with the development of shock .

Objective finding

- Nausea, vomiting, stoppage of gas and stool, persistent pain;
- pulse rapid, thready, skin cold, covered with sweat.

Diagnosis

Anamnesis and physical examination alert us to a possible torsion - the abdomen is distended, diffusely painful (maximum in the lower abdomen), muscular defense . By palpation per vaginam - extremely painful resistance next to the uterus. Definitive diagnosis will be determined by USG and laparoscopy . But the finding on the abdomen is more often an indication for an acute laparotomy .

Therapy

The extent of the operation is governed by the vitality of the adnexa after blood supply is restored. In favorable cases, we perform only cystectomy or partial resection of the ovary after derotation. Adnexectomy is the solution in an unfavorable condition with necrosis.

Sudden abdominal events in pregnancy

Sudden onset conditions that develop from full health, with a rapid course. The main symptom is abdominopelvic pain. These are serious conditions threatening both the fetus and the mother, so rapid diagnosis and subsequent therapy are essential.

Common causes of NPB in pregnant women:

- Gastrointestinal (appendicitis, cholecystitis, ileus);
- gynecological (torsion of the adnexa);
- urological (nephrolithiasis, pyelonephritis);
- vascular.

Changes in the anatomical conditions in the abdominal cavity, related to pregnancy, can affect the blood supply of the abdominal organs, thereby disrupting the outflow of urine and intestinal passage. They also cause abdominal discomfort (vomiting, abdominal pain, meteorism, constipation). Increases in hormonal levels (estrogens, progesterones) contribute to the formation of gallstones and a decrease in the tone of the gallbladder. The most common cause is appendicitis.

Appendicitis rarely occurs during pregnancy most often around the 3rd month of pregnancy. It threatens the life of the mother and the fetus. During pregnancy, due to hormones, the appendix is congested and soaked, it is more easily susceptible to gangrene. Protrusion caecum and its isolation by the uterus does not allow the inflammation

to be limited, it easily transfers to the uterus and leads to its contractions.

Diagnostics

Diagnosis is difficult because uterus interferes with the examination, displacing the worm from its normal position. From the 4th month, the point of pain moves upwards (in the 8th-9th month, it lies under the arch of the ribs). In addition, some symptoms of appendicitis are normal during pregnancy - nausea, vomiting, peristaltic disorders, tachycardia. Another important symptom of peritoneal irritation – *défense musculaire*, as the uterus prevents contact with the peritoneum.

- **Alders' test** – we turn the pregnant woman onto her left side with constant pressure on the painful area, if the pain stops, it is of uterine origin and does not indicate appendicitis.
- **Sitkovski's sign** - on the contrary, when turning over on the right side, pain appears in the ileocecal area, this indicates appendicitis.

Links

References

- ČECH, Evžen – HÁJEK, Zdeněk – MARŠÁL, Karel. *Obstetrics*. 2. edition. Grada, 2006. 544 pp. ISBN 80-247-1303-9.
- BRECKWOLDT, Meinert. *Gynecology and Obstetrics*. 1. edition. Osveta, 1997. 648 pp. ISBN 80-88824-56-7.
- BENEŠ, Jiří. *Questions for the state exam in Gynecology and Obstetrics* [online]. ©2008. [cit. 2011]. <http://jirben2.chytrak.cz/materialy/gynda_JB.doc>.
- MÁRA, Michal. *Sudden abdominal events in gynecology, case reports* [lecture for subject Pre-graduate internship in gynecology and obstetrics, specialization Gynecology and Obstetrics, 1. LF UK]. Praha. -. Available from <<https://el.lf1.cuni.cz/gpmara2a>>.
- ROSENDORF, J.; LIŠKA, V.; PÁLEK, R.; TÈŠKA, V., Sudden abdominal events in pregnancy: a retrospective study of pregnant patients hospitalized for abdominal pain. *For doctors*. 2020, year 99, No. 3, pp. 131-135. Also available from: <https://www.prolekare.cz/casopisy/rozhledy-v-chirurgii/2020-3-2/nahle-prihody-brisni-v-tehotenstvi-retrospektivni-studie-gravidnich-pacientek-hospitalizovanych-pro-stomach-pain-122065>
- Gynecology and obstetrics (Martius 2005).